

## Diabetic Papillopathy in One Eyed Patient, an Incidental Diagnosis Based on Therapeutic Response

Sandhya R<sup>1</sup>, Sumanth IM<sup>2</sup>, Sai Monisha Jammula<sup>3</sup>

### Abstract

A 52 years old one eyed male presented with history of blurring of in right eye since 7 days which was rapidly progressing in onset and painless. Dilated fundoscopic examination of right eye showed pallid disc edema, venous dilation and a flame shaped superficial retinal hemorrhage in the peripapillary area with inferior altitudinal defect. Left eye was pthysical with no PL. On investigation patient was diagnosed to have diabetes mellitus with morbidly deranged metabolic status. This case was posed a diagnostic challenge as the clinical picture did not typically fit into the diagnosis of optic neuritis as the color vision was normal, RAPD could not be confirmed, disc showed pallid edema: AION was a differential diagnosis because of pallid edema or the disc, peripapillary hemorrhage & altitudinal defect. The discovery of Diabetes mellitus on routine blood sugar estimation added Diabetic papillopathy to the list of differential diagnoses. However, it was the rapid therapeutic response with oral anti hypoglycemic agents in the form of improved vision & fields that led to the incidental diagnosis of Diabetic papillopathy.

**Keywords:** Altitudinal defect; Anterior ischemic optic neuropathy Diabetic Papillopathy; Pallid edema, Pthysis, RAPD.

### How to cite this article:

Sandhya R, Sumanth IM, Sai Monisha Jammula. Diabetic Papillopathy in One Eyed Patient, an Incidental Diagnosis Based on Therapeutic Response. Ophthalmol Allied Sci. 2019;5(3):309-312

### Introduction

Diabetic papillopathy is believed to be a rare occurrence of diabetes mellitus seen in patients with both Type 1 and Type 2 diabetes mellitus (T2DM). Its signs and symptoms often confound or overlap with non arteritic anterior ischemic optic neuropathy (NAION), as both these conditions are due ischemic process. While its been described that diabetic papillopathy as an asymptomatic, benign condition with no or minimal visual impact, which worsens with sudden glycemic control. Here we

describe a case of diabetic papillopathy in newly diagnosed diabetes mellitus patients presented with moderate visual disturbance which resolved with good glycemic control, somewhat contrary to the described pattern in literature.

### Case Report

A 52 year-old male presented to OPD with blurring of vision in right eye since 7 days which was rapidly progressing in onset and painless. He noticed this while he tried reading & writing in the morning. There were no other ocular or systemic symptoms. He gave history of trauma to left eye with stick 40 years back followed by complete loss of vision in left eye since then. No other details were forthcoming.

He was not a known smoker or alcoholic. General physical examination was essentially normal; Blood pressure 120/80 mm Hg. Systemic examination of cardiovascular, respiratory,

**Author Affiliation:** <sup>1</sup>Professor, <sup>2,3</sup>Junior Resident, Department of Ophthalmology, Sri Devaraj Urs Medical College, Tamaka, Kolar, Karnataka 563101, India.

**Corresponding Author: Sumanth I M**, Junior Resident, Department of Ophthalmology, Sri Devaraj Urs Medical College, Tamaka, Kolar, Karnataka 563101, India.

**E-mail:** [i.sumanthmohan@gmail.com](mailto:i.sumanthmohan@gmail.com)

**Received on** 30.08.2019, **Accepted on** 23.10.2019

abdomen & nervous system systems were within normal. At presentation the BCVA of right eye was 6/18 (p), with no significant refractive error: color vision was normal. Slit lamp examination

of anterior segment was normal, pupil was 3 mm, round, reactive and well sustained. + 90 D examination showed no vitreous reaction, disc margin was blurred all around with 2 mm elevation

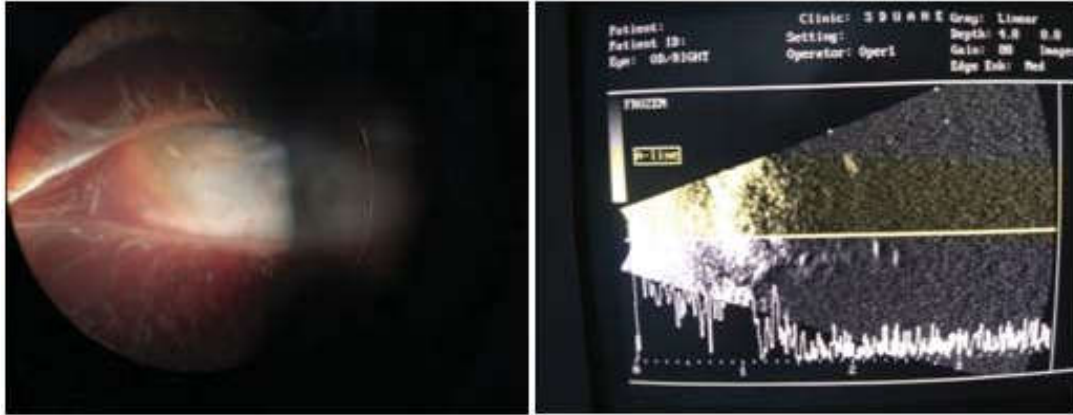


Fig. 1: Left eye of the patient with B scan

of optic disc. Vessels were arising from centre of the disc, there was venous dilation with A:V ratio 2:4. A single flame shaped superficial retinal hemorrhage was noted in the peripapillary area

at 9'o clock position. Macula appeared normal with dull foveal reflex. IOP was 12 mm Hg. Gonioscopy showed open angles with Shaffer's grading 3 in all quadrants.

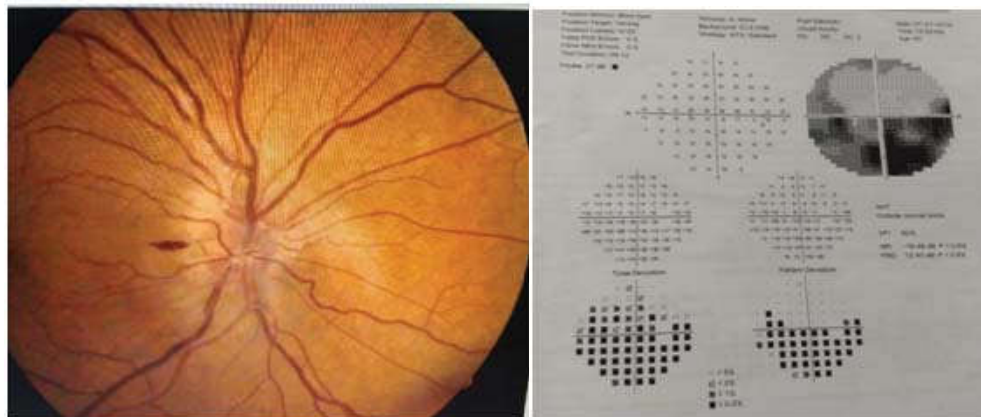


Fig. 2: Right eye fundus picture and fields on day 1

OCT showed disc edema extending to peripapillary area, there was no hyperemia. Macula & peripheral retina were normal & there were no other gross abnormalities. On examination left eye was pthysical with no PL negative. Axial length was 13 mm with hyper intense lesions in the cavity suggestive of calcifications and sclerosed sclerochoroidal wall noted on USG B scan (Fig. 1).

A working diagnosis of Disc Oedema Right eye was made & evaluated. Visual fields by confrontation test showed constricted field infero-temporally and infero-nasally & HFA showed

inferior altitudinal field defect.

On day two Metabolic work up revealed deranged glucose metabolism, with HbA1C value of 7.5%, fasting blood sugar 330 mg/dl and post prandial 441 mg/dl, ESR 10 mm/hr. All other parameters were within the normal range. Neurological evaluation was repeated and was reported normal. CT scan was done to rule out any intracranial space occupying lesions & any other pathology (Fig. 2).

Differential diagnosis of Optic neuritis, Non-

artritic–Anterior ischemic Optic Neuropathy, diabetic papillopathy were considered. Moderate painless visual disturbance, normal color vision & pale edema were not typical of Optic neuritis. Peripapillary hemorrhage, pale disc edema, altitudinal filed defect were suggestive of anterior

ischemic optic neuropathy: ESR was normal. Patient was started on oral hypoglycemic drugs in view of deranged sugar levels, also on oral multivitamin tablets and on topical NSAID eye drops. Steroids were not started due to the metabolic status of patient with consultation of physician.

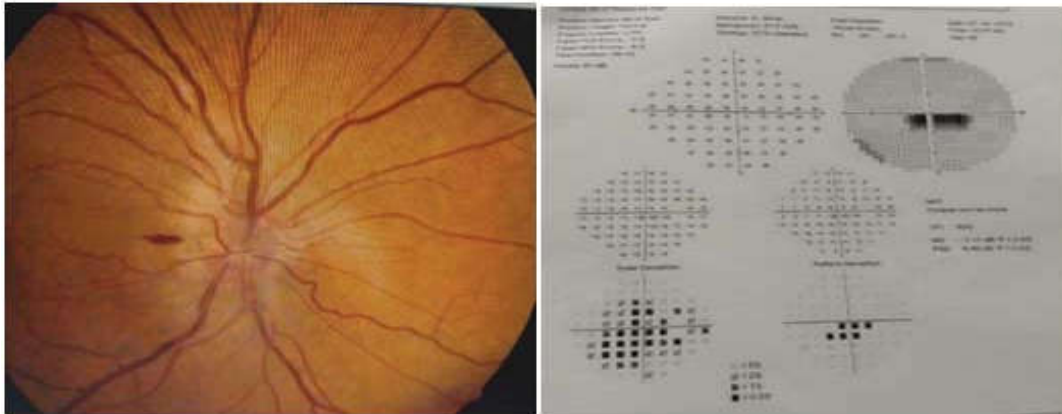


Fig. 3: Right eye fundus picture and fields on *day 5*

On day 3, fundus of the patient showed segmental disc pallor from 9 O'clock to 12 O'clock position, rest being the same.

On day 5 patient was symptomatically better. Visual acuity was 6/12. The fundus picture remained the same. Repeat HFA showed improvement in field of vision of the patient. It was decided to continue conservative management with emphasis on metabolic state of the patient (Fig. 3).

At *two weeks* follow up, visual acuity had improved to 6/9, visual fields revealed just a small residual paracentral scotoma and the patient had achieved stable glyceamic control.

## Discussion

Diabetic papillopathy is a rare diagnosis of exclusion. It was first described in 1971 and has been reported in patients with both type 1 and type 2 diabetes mellitus. It typically occurs bilaterally, has only mild to moderate effects on visual acuity and visual fields are typically restricted.<sup>1,2</sup> It may occur in the absence of diabetic retinopathy. The exact pathogenesis is unclear, but is believed to occur due to disruption of the peripapillary vasculature.<sup>3</sup> The degree of diabetic retinopathy in patients with diabetic papillopathy tends to be mild, and it is believed that diabetic papillopathy is a separate entity rather than an extension of diabetic retinopathy.<sup>4</sup> Current accepted criteria

for the diagnosis of diabetic papillopathy include: Confirmed diagnosis of diabetes (type 1 or type 2), optic disc oedema, and absence of substantial optic nerve dysfunction, normal ICP and lack of nerve inflammation, infection, or infiltration.<sup>5</sup> In patients with diabetes who start intensive insulin treatment, incidence of diabetic papillopathy has been associated with failure to downregulate retinal blood flow and atrend toward increased retinal perfusion.<sup>6</sup>

Studies have also shown that cases having isolated peripapillarysubretinal hemorrhages may be due to crowded optic disc which can predispose to ischemic neuropathies.<sup>7</sup> Acute onset of blurring of vision in a middle aged one eyed patient with pale oedema and one peripapillary hemorrhage pointed towards an underlying ischemic pathology.

Patients with non-arteritic anterior ischemic optic neuropathy are typically older than 50 years & predisposed those with crowded optic nerves. Typically the presentation is with sudden visual loss sometimes with mild, non-specific periocular pain which may sometimes continue to worsen for up to 30 days,<sup>8</sup> Altitudinal field defects are usually present and clinically there may be no significant improvement in visual function.

Unilateral presentation of rapid visual disturbance with pallid edema, one NFL peri papillary hemorrhage & altitudinal filed defect in this one eyed patient were supporting the differential diagnosis of NA-AION. But in this case no clues such as small discs

could be obtained as the other eye was phthisical. The rapid recovery & absence of typical RAPD were non-conforming. Most patients with acquired optic neuropathy will have dyschromatopsia, which may be restricted only to the affected area corresponding to the sectorial optic nerve dysfunction. Sometimes the speed with which color plates are recognized may be the only difference in the affected eye.<sup>9</sup> Normal color vision at the day of presentation with a pallid disc edema was going against optic neuropathy. Optic neuritis is usually seen in women, mostly in their second, third and fourth decades of life, who present with subacute visual loss with (in over 90%) pain on eye movements. Only a 30% of patients with optic neuritis have visible optic nerve head oedema.<sup>10</sup> Less than 5% of patients have peripapillary hemorrhages. Here it was middle man with pallid disc edema which was painless and having peripapillary hemorrhage. Rapid therapeutic response to conservative management along with glycemic control confirmed the clinical suspicion of Atypical diabetic papillopathy: Albeit the absence of other features of diabetic retinopathy.<sup>11</sup>

### Conclusion

Rapid onset of significant unilateral visual diminution in a young adult male is conventionally investigated on the lines of Optic neuritis. The challenges in this patient was, that he was one eyed; RAPD could not be assessed, the optic disc clues in the fellow eye such as crowded disc or small cup or other anomalies could not be assessed. The pallid edema was another distracter. Also, the choice of treatment options was critical for this one eyed patient. The routine metabolic work up was the key to the hitherto undiagnosed Diabetes mellitus. Despite Optic neuritis being the first differential diagnosis, steroid regimen was withheld as we considered metabolic control of diabetes the

priority. However, the rapid therapeutic response with oral anti-hypoglycemic agents led to the revised diagnosis of Diabetic papillopathy. VEP and FFA at presentation and at serial follow up can give more clues to this clinical enigma.

### References

1. Regillo CD, Brown GC, Savino PJ, *et al.* Diabetic Papillopathy: Patient characteristics and fundus findings. *Arch Ophthalmol.* 1995;113:889-94.
2. Bayraktar Z, Alacali N, Bayraktar S. Diabetic papillopathy in type II diabetic patients. *Retina* 2002;22:752-58.
3. Kroll P, Wiegand W, Schimdt J. Vitreopapillary traction in proliferative diabetic vitreoretinopathy. *Br J Ophthalmol.* 1999;83:261-64.
4. Regillo CD, Brown GC, Savino PJ Diabetic papillopathy: Patient characteristics and fundus findings. *Arch Ophthalmol.* 1995;113:889-95.
5. Arnold AC. Ischemic optic neuropathy. In: Miller NR, Newman NJ, Editors. *Walsh and Hoyt's Clinical Neuro-Ophthalmology*, 6<sup>th</sup> edition. Philadelphia: Lippincott Williams & Wilkins; 2005.pp.377-78.
6. Grunwald JE, Brucker AJ, Braunstein SN. Strict metabolic control and retinal blood flow in diabetes mellitus. *Br J Ophthalmol.* 1994;78:598-604.
7. Doro S, Lessell S. Cup-disc ratio and ischemic optic neuropathy. *Arch Ophthalmol.* 1985;103:1143-144.
8. Bayraktar Z, Alacali N, Bayraktar S. Diabetic papillopathy in type II diabetic patients. *Retina.* 2002;22:752-58.
9. Behbehani R. Clinical approach to optic neuropathies. *Clin Ophthalmol.* 2007;1(3):233-46.
10. The clinical profile of optic neuritis. Experience of the optic neuritis treatment trial. Optic Neuritis Study Group. *Arch Ophthalmol.* 1991;109:1673-678.
11. Margolin E. The swollen optic nerve: An approach to diagnosis and management. *Practical Neurology.* 2019;19:302-309.